

Conclusion Poor cerebral perfusion on the venous microvascular profile predicts ischemic lesion growth and final infarct core volume in AIS-LVO patients treated with thrombectomy.

Disclosures T. Faizy: None. R. Kabiri: None. M. Leipzig: None. G. Brooks: None. S. Christensen: None. F. Flottmann: None. M. Lansberg: None. G. Albers: None. J. Fiehler: None. M. Wintermark: None. J. Heit: None.

O-028 THE INTRASACULAR SEAL® DEVICE: IMPROVED FLEXIBILITY AND HEALING

¹A Kraitem, ¹M Gounis*, ¹Z Vardar, ¹R King, ¹E Langan, ²T Wolfe, ³A Badruddin, ⁴E Periera, ⁵B Follmer, ⁵A Rosqueta, ⁶O Zaidat. ¹Radiology, University of Massachusetts, Worcester, MA; ²Aurora Neuroscience Innovation Institute, Aurora Health, Milwaukee, WI; ³Neurology, Community Hospital, Munster, IN; ⁴Vascular and Interventional Radiology, Biscayne Medical Arts Center, Miami, FL; ⁵RandD, Galaxy Therapeutics, Brookfield, WI; ⁶Endovascular Neurosurgery and Stroke, St Vincent Medical Center, Toledo, OH

10.1136/neurintsurg-2020-SNIS.28

Background The new generation of intrasaccular flow disruptors offers several potential advantages in aneurysm treatment.^{1,2} However, questions regarding risks for thromboembolic complications^{3,4} and long-term treatment durability remain. We study the safety and effectiveness of three Galaxy Therapeutics Seal® intrasaccular prototypes: A, B, and C (Galaxy Therapeutics LLC, Brookfield, WI).

Methods Aneurysms were created in thirteen rabbits and one of 3 Seal devices were implanted. High frequency optical coherence tomography (HF-OCT) and Digital Subtraction Angiography (DSA) was performed 4- and 12-weeks post-implant. After 12 weeks, the parent vessel and the aneurysm were explanted for histological analysis. One rabbit developed symptoms consistent with a lumbar spine injury and was euthanized and explanted at day 56.

Results 12-week DSA and OCT images demonstrated 8 animals had a satisfactory aneurysm occlusion (group 1: complete blood flow disruption or contrast filling in marker recess) and 4 into group 2 (residual neck or aneurysm). The percentage of neointimal coverage of the device at four-weeks was greater for group 1 ($78 \pm 22.6\%$) than for group 2 ($37 \pm 4.7\%$) ($p=0.006$) which persisted at 12-weeks ($87.5 \pm 14\%$ vs. $41 \pm 3.1\%$ respectively; $p=0.004$). There was no statistical difference between groups 1 and 2 in either baseline neck gap areas ($0.8 \pm 0.64 \text{ mm}^2$ vs. $2.6 \pm 1.42 \text{ mm}^2$, respectively; $p=0.808$) nor in baseline neck gap volumes ($26 \pm 26 \text{ mm}^3$ vs. $113.11 \pm 134.17 \text{ mm}^3$, respectively; $p=0.361$). Representative examples of pathology are shown in the figure 1.

Conclusion Preliminary evidence in this preclinical study highlights advantages of a new generation of intrasaccular aneurysm

embolization technology in terms of flexibility and optimization of healing features, particularly in the A and C cohorts.

REFERENCES

1. *Radiology* 2014;**273**:194–201.
2. *J Neurointerv Surg* 2019;**11**:1150–1154.
3. *World Neurosurg* 2018;**109**:e183–e193.
4. *J Neurointerv Surg* 2018;**10**:553–559.

Disclosures A. Kraitem: None. M. Gounis: 1; C; Research grant to institution to fund experiments by Galaxy Therapeutics. Z. Vardar: None. R. King: None. E. Langan: None. T. Wolfe: 4; C; Founder, Galaxy Therapeutics. A. Badruddin: 4; C; Founder, Galaxy Therapeutics. E. Periera: 4; C; Founder, Galaxy Therapeutics. B. Follmer: 5; C; Galaxy Therapeutics. A. Rosqueta: 5; C; Galaxy Therapeutics. O. Zaidat: 4; C; Founder, Galaxy Therapeutics.

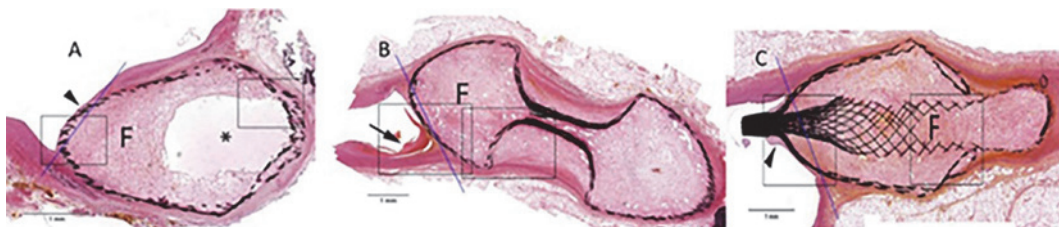
O-029 OUTCOMES OF ENDOVASCULAR TREATMENT OF VEIN OF GALEN ANEURYSMAL MALFORMATION IN NEONATES

P Seleznev, K Orlov*, V Berestov, A Gorbatykh, D Kisilitsyn, T Shayakhmetov, N Strelnikov. Meshalkin National Medical Research Center, Novosibirsk, Russian Federation

10.1136/neurintsurg-2020-SNIS.29

Objective Vein of Galen aneurysmal malformation is a rare congenital cerebrovascular disorder whose natural course has almost no favorable outcomes (<1%). Our objective was to analyze the outcomes of endovascular treatment of patients with vein of Galen aneurysmal malformation (VGM) during the first days of their life.

Materials and Methods During the period between January 2013 and February 2020, 52 patients with vein of Galen malformations were operated on at the National Medical Research Center named after Academician E.A. Meshalkin. Eleven of these patients were younger than 10 days when surgery was performed. Twelve endovascular embolization sessions were conducted via a transarterial approach. Cyanacrylate glue was used in 10 cases (mural VGMs); in one case, Phil 25 non-adhesive liquid embolic system was used and two embolization stages were performed (choroidal VGM). All patients were hospitalized in an intensive care unit having the Bicêtre score of 10–12. Prior to surgery, all patients underwent cardiac ultrasonography (that involved measuring pulmonary artery pressure) and neurosonography that involved measuring the linear blood flow velocity (LBFV) in the vein of Galen and afferent vessels. All patients had pronounced pulmonary hypertension; LBFV in the vein of Galen was $\geq 0.6 \text{ m/s}$.



Abstract O-028 Figure 1 H&E stains for the three prototypes (A), (B), and (C) 12-weeks following implant. Solid line=approximate aneurysm neck. Arrowhead = mature and stable neointima covering device; F= fibrovascular tissue partially filling the fundus; A: asterisk = sequestered cystic space within the fundus (not connected to parent vessel). B: arrow=fibrin thrombus in parent artery recess at neck